



## Eosinophilic pneumonia: remember topical drugs as a potential etiology

Olívia Meira Dias<sup>1,a</sup>, Ellen Caroline Toledo do Nascimento<sup>2,b</sup>,  
Rodrigo Caruso Chate<sup>3,c</sup>, Ronaldo Adib Kairalla<sup>1,d</sup>, Bruno Guedes Baldi<sup>1,e</sup>

### TO THE EDITOR:

A 32-year-old female patient was admitted to the emergency room with a 20-day history of asthenia, myalgia, fever, and dry cough. She reported no dyspnea or wheezing. There was no relevant exposure history except for the use of minocycline for 1 month as a topical treatment for facial acne. In addition, the patient reported no history of medication use, allergies, smoking, or illicit drug use.

Her physical examination upon admission was unremarkable, the patient being afebrile. There was no skin rash. Lung auscultation was normal. Her heart rate was 87 bpm, her respiratory rate was 18 breaths/min, and her SpO<sub>2</sub> was 98% on room air.

Laboratory tests showed leukocytosis ( $13 \times 10^9$  cells/L), with an eosinophil count of 1,300 cells/ $\mu$ L. Her C-reactive protein levels were elevated (206 mg/dL; reference value, < 10 mg/dL). Her platelet count, electrolyte levels, renal function, and liver function were all normal. Point-of-care tests for influenza and dengue were negative, as were urinalysis results. Rheumatoid factor, antinuclear factor, and antineutrophil cytoplasmic antibody test results were all negative. IgE levels were elevated (374 kU/L; reference value, < 100 kU/L). Examination of the stool for ova and parasites was negative.

An HRCT scan of the chest showed bilateral consolidations with ill-defined margins, predominantly at the lung apices and periphery (Figures 1A, B, and C). The patient underwent bronchoscopy with BAL and transbronchial biopsy. BAL fluid cytology revealed a predominance of eosinophils (35%), being negative for malignant cells. In addition, microbiological analysis of the BAL fluid was negative. The transbronchial biopsy revealed alveolar/interstitial inflammatory cell infiltrate (with a predominance of eosinophils and lymphocytes), as well as foci of non-necrotizing granulomatous inflammation in the arteriole walls (Figures 1D and E). A diagnosis of minocycline-induced chronic eosinophilic pneumonia (EP) was made after exclusion of other causes of peripheral and pulmonary eosinophilia, being based on HRCT findings consistent with the disease. Peripheral eosinophilia, dyspnea, and CT changes resolved after discontinuation of minocycline and initiation of prednisone at 30 mg/day.

EP comprises a heterogeneous group of diseases that share pulmonary eosinophilia as a common feature. A diagnosis of EP can be made on the basis of at least one of the following criteria: peripheral eosinophilia

associated with pulmonary opacities on imaging; surgical or transbronchial biopsy findings of eosinophilia; and an increase in the proportion of eosinophils in BAL fluid.<sup>(1)</sup>

Although EP can present as acute respiratory failure (especially in patients with acute EP), the prognosis is generally good. Clinical history taking, investigation of extrapulmonary involvement, and evaluation of patient exposure are essential in making a diagnosis of EP. Because of the presence of nonspecific symptoms, diagnosis is often delayed.<sup>(1)</sup>

Although EP can be idiopathic, epidemiological factors should be considered when investigating pulmonary eosinophilia, including exposure to parasites (including *Ascaris* spp., *Ancylostoma* spp., *Necator* spp., and *Strongyloides* spp.), exposure to inhalation agents, first-time smoking, changes in smoking habits, toxic inhalation, medication use, and illicit drug use, as well as a history of asthma and atopy.<sup>(1-4)</sup> Drugs have been increasingly associated with EP; a complete and up-to-date list can be found at [www.pneumotox.com](http://www.pneumotox.com).<sup>(5)</sup>

Although there have been reports of peripheral eosinophilia in patients with EP, it is not always observed in such patients, especially those with acute EP.<sup>(6)</sup> In such patients, BAL or biopsy can provide insight as to the likelihood of peripheral eosinophilia (eosinophil levels above 25% in differential cell counts in BAL fluid).

In the case reported here, the final diagnosis was chronic EP, an insidious disease with symptoms that range from 2 weeks to 4 weeks in duration. In patients with secondary EP, symptoms commonly appear after radiation therapy for breast cancer and exposure to drugs or parasites, and might be associated with collagen diseases, such as rheumatoid arthritis. Female patients in the 30- to 40-year age bracket are most commonly affected. Major symptoms include dry cough, dyspnea, fever, asthenia, and weight loss. Unlike patients with acute EP, those with chronic EP rarely develop acute respiratory failure.<sup>(3)</sup>

EP secondary to minocycline is rare, being underreported because minocycline is used as a topical agent in the treatment of acne vulgaris and is therefore not considered to be a drug or medication. The prognosis of minocycline-induced EP is often good.<sup>(7)</sup>

Drug-induced EP can mimic idiopathic acute EP or chronic EP on imaging. In patients with idiopathic acute EP, characteristic CT findings include diffuse interstitial infiltrates, patchy alveolar infiltrates, and diffuse

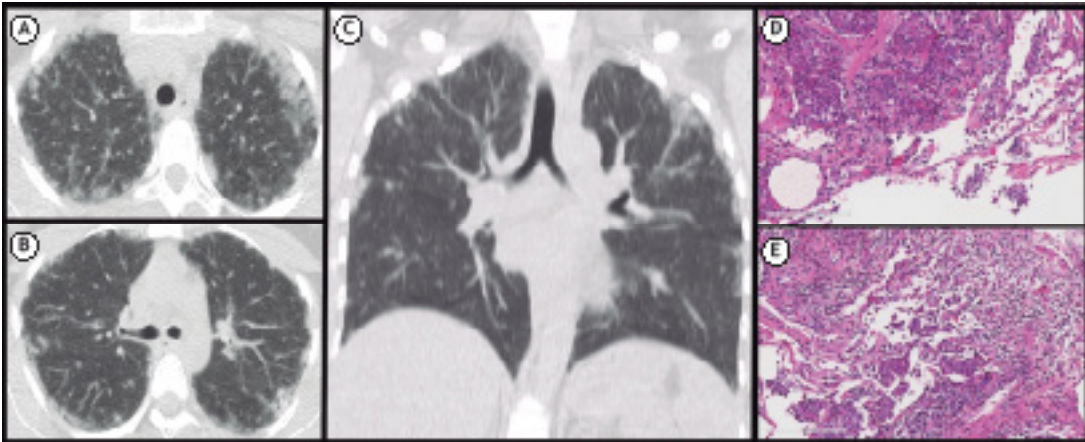
1. Divisão de Pneumologia, Instituto do Coração – InCor – Hospital das Clínicas, Faculdade de Medicina, Universidade de São Paulo, São Paulo (SP) Brasil.

2. Departamento de Patologia, Hospital das Clínicas, Faculdade de Medicina, Universidade de São Paulo, São Paulo (SP) Brasil.

3. Divisão de Radiologia, Instituto do Coração – InCor – Hospital das Clínicas, Faculdade de Medicina, Universidade de São Paulo, São Paulo (SP) Brasil.

a. <http://orcid.org/0000-0002-5926-2975>; b. <http://orcid.org/0000-0002-2981-1419>; c. <http://orcid.org/0000-0002-4193-7647>;

d. <http://orcid.org/0000-0001-7194-0479>; e. <http://orcid.org/0000-0002-9609-5117>



**Figure 1.** In A and B, axial HRCT scans of the chest. In C, coronal HRCT scan of the chest. Note bilateral consolidations with ill-defined margins, predominantly at the lung apices and periphery. Note also the presence of reticulation. In D, transbronchial biopsy specimen showing alveolar/interstitial inflammatory cell infiltrate, with a predominance of eosinophils and lymphocytes (H&E staining; magnification,  $\times 100$ ). In E, expansion of the pulmonary interstitium by an inflammatory cell infiltrate composed of lymphocytes, plasma cells, and eosinophils. In the upper left corner, note the non-necrotizing granulomatous inflammation in the arteriole walls (H&E staining; magnification,  $\times 100$ ).

ground-glass infiltrates. A crazy-paving pattern and bilateral pleural effusions can also be seen.<sup>(8)</sup>

In the case reported here, pulmonary consolidations had a patchy, peripheral distribution. In addition, subpleural confluent consolidations were found at the lung apices, resembling a photographic negative of cardiogenic pulmonary edema, classically described in idiopathic chronic EP.<sup>(9,10)</sup> Other common CT findings include the reversed halo sign, small nodules, septal thickening, and reticulation.<sup>(8)</sup> The most common radiological differential diagnosis is cryptogenic organizing pneumonia, in which pulmonary consolidations and migratory alveolar infiltrates can also occur.<sup>(11)</sup>

Histopathologically, EP is characterized by prominent eosinophilic infiltration of the alveolar spaces and associated interstitium, accompanied by a fibrinous exudate. The lung architecture is typically preserved. Eosinophilic microabscesses, non-necrotizing nongranulomatous vasculitis, and occasional multinucleated giant cells can also be found. The vessel infiltration observed in patients with EP should not be mistaken for that observed in patients with Churg-Strauss syndrome. In the latter, vasculitis

is characterized by intimal and medial infiltration by chronic inflammatory cells, including numerous eosinophils; it can show granulomatous features or contain numerous giant cells reminiscent of giant cell arteritis, and fibrinoid necrosis is sometimes present.<sup>(12)</sup> In addition, necrotizing granulomas are typically found in the adjacent parenchyma, being composed of large foci of necrosis surrounded by a rim of epithelioid histiocytes (i.e., "palisaded granulomas").<sup>(12)</sup>

The differential diagnosis of EP includes the following: cryptogenic organizing pneumonia, particularly in the clinical context of collagen vascular diseases such as myositis, mixed connective tissue disease, and systemic lupus erythematosus; idiopathic hypereosinophilic syndrome; and Churg-Strauss syndrome. The last two are generally associated with a more pronounced extrathoracic involvement and longer symptom duration.

The prognosis of EP is usually excellent, which is due to its responsiveness to corticosteroids. In general, prednisone is used at  $0.5 \text{ mg} \cdot \text{kg}^{-1} \cdot \text{day}^{-1}$  for two weeks to six months with progressive tapering, depending on disease severity. In some cases, withdrawal from exposure is sufficient for clinical improvement. Re-exposure has been reported to result in recurrence.<sup>(4)</sup>

## REFERENCES

- Campos LE, Pereira LF. Pulmonary eosinophilia. *J Bras Pneumol.* 2009;35(6):561-73. <https://doi.org/10.1590/S1806-37132009000600010>
- Cottin V, Cordier JF. Eosinophilic pneumonias. *Allergy.* 2005;60(7):841-57. <https://doi.org/10.1111/j.1398-9995.2005.00812.x>
- Katz U, Shoenfeld Y. Pulmonary eosinophilia. *Clin Rev Allergy Immunol.* 2008;34(3):367-71. <https://doi.org/10.1007/s12016-007-8053-y>
- De Giacomi F, Decker PA, Vassallo R, Ryu JH. Acute Eosinophilic Pneumonia: Correlation of Clinical Characteristics With Underlying Cause. *Chest.* 2017;152(2):379-385. <https://doi.org/10.1016/j.chest.2017.03.001>
- PNEUMOTOX ON LINE: The Drug-Induced Respiratory Disease Website [homepage on the Internet]. Dijon, France: Philippe Camus; v2.2 [cited 2017 Oct 7]. Available from: [www.pneumotox.com](http://www.pneumotox.com)
- Buelow BJ, Kelly BT, Zafra HT, Kelly KJ. Absence of Peripheral Eosinophilia on Initial Clinical Presentation Does Not Rule Out the Diagnosis of Acute Eosinophilic Pneumonia. *J Allergy Clin Immunol Pract.* 2015;3(4):597-8. <https://doi.org/10.1016/j.jaip.2015.01.008>
- Cottin V. Eosinophilic Lung Diseases. *Clin Chest Med.* 2016;37(3):535-56. <https://doi.org/10.1016/j.ccm.2016.04.015>
- Price M, Gilman MD, Carter BW, Sabloff BS, Truong MT, Wu CC. Imaging of Eosinophilic Lung Diseases. *Radiol Clin North Am.* 2016;54(6):1151-1164. <https://doi.org/10.1016/j.rcl.2016.05.008>
- Jeong YJ, Kim KI, Seo IJ, Lee CH, Lee KN, Kim KN, et al. Eosinophilic lung diseases: a clinical, radiologic, and pathologic overview.

- Radiographics. 2007;27(3):617-37; discussion 637-9. <https://doi.org/10.1148/rg.273065051>
10. Cherian SV, Thampy E. 'Photographic negative of pulmonary oedema': a classical radiographic pattern of chronic eosinophilic pneumonia. *Postgrad Med J*. 2015;91(1077):411-2. <https://doi.org/10.1136/postgradmedj-2015-133443>
  11. Drakopanagiotakis F, Paschalaki K, Abu-Hijleh M, Aswad B, Karagianidis N, Kastanakis E, et al. Cryptogenic and secondary organizing pneumonia: clinical presentation, radiographic findings, treatment response, and prognosis. *Chest*. 2011;139(4):893-900. <https://doi.org/10.1378/chest.10-0883>
  12. Katzenstein AL. Diagnostic features and differential diagnosis of Churg-Strauss syndrome in the lung. A review. *Am J Clin Pathol*. 2000;114(5):767-72. <https://doi.org/10.1309/F3FW-J8EB-X913-G1RJ>