

# Case Report

## Severe paraquat poisoning: clinical and radiological findings in a survivor\*, \*\*

Intoxicação grave por paraquat: achados clínicos e radiológicos em um sobrevivente

Fábio Fernandes Neves, Romualdo Barroso Sousa, Antônio Pazin-Filho, Palmira Cupo, Jorge Elias Júnior, Marcello Henrique Nogueira-Barbosa

### Abstract

Paraquat is a nonselective contact herbicide of great toxicological importance, being associated with high mortality rates, mainly due to respiratory failure. We report the case of a 22-year-old male admitted to the emergency room with a sore throat, dysphagia, hemoptysis, and retrosternal pain after the ingestion of 50 mL of a paraquat solution, four days prior to admission. Chest CT scans revealed pulmonary opacities, pneumomediastinum, pneumothorax, and subcutaneous emphysema. The patient was submitted to two cycles of immunosuppressive therapy with cyclophosphamide, methylprednisolone, and dexamethasone. The pulmonary gas exchange parameters gradually improved, and the patient was discharged four weeks later. The clinical and tomographic follow-up evaluations performed at four months after discharge showed that there had been further clinical improvement. We also present a brief review of the literature, as well as a discussion of the therapeutic algorithm for severe paraquat poisoning.

**Keywords:** Paraquat/poisoning; Pulmonary fibrosis; Pneumothorax.

### Resumo

O paraquat é um herbicida não seletivo que possui grande importância toxicológica, sendo associado a altas taxas de letalidade, devidas principalmente à insuficiência respiratória. Este é o relato do caso de um homem de 22 anos admitido no departamento de emergência com queixa de dor de garganta, disfagia, hemoptise e dor retroesternal. Ele relatava a ingestão de cerca de 50 mL de uma solução de paraquat quatro dias antes da admissão hospitalar. A TC de tórax exibiu opacidades pulmonares, pneumomediastino, pneumotórax e enfisema subcutâneo. O paciente foi submetido a dois ciclos de terapia imunossupressora com ciclofosfamida, metilprednisolona e dexametasona. Os parâmetros gasométricos progressivamente melhoraram, e o paciente recebeu alta hospitalar após quatro semanas. Decorridos quatro meses da alta, o paciente foi submetido a controles clínico e tomográfico, os quais confirmaram a melhora clínica. Apresentamos também uma revisão sucinta da literatura, bem como uma discussão do processo de decisão terapêutica para intoxicação grave por paraquat.

**Descritores:** Paraquat/envenenamento; Fibrose pulmonar; Pneumotórax.

### Introduction

Paraquat is a widely used, nonselective contact herbicide of great toxicological importance and is associated with high mortality rates.<sup>(1)</sup> In humans who have ingested a significant quantity of paraquat, death usually occurs within two to three weeks, resulting from acute renal failure, hepatitis, and, mainly, respiratory failure due to pulmonary inflammation and fibrosis.<sup>(2)</sup>

### Case report

A 22-year-old male was admitted to the emergency department with a sore throat, dysphagia, hemoptysis, and retrosternal pain. He had attempted suicide by ingesting 50 mL of a paraquat solution four days prior to admission and had been treated, at another facility, with gastric lavage and administration of activated charcoal. It is of note that he had attempted suicide previously, on more than one occasion.

\* Study carried out at University of São Paulo at Ribeirão Preto School of Medicine, Ribeirão Preto, Brazil.

Correspondence to: Fábio Fernandes Neves. Centro de Estudos de Emergências em Saúde. Rua Bernardino de Campos, 1000, Higienópolis, CEP 14015-130, Ribeirão Preto, SP, Brasil.

Tel 55 16 3602-1258. E-mail: fabionenes@hcrp.usp.br

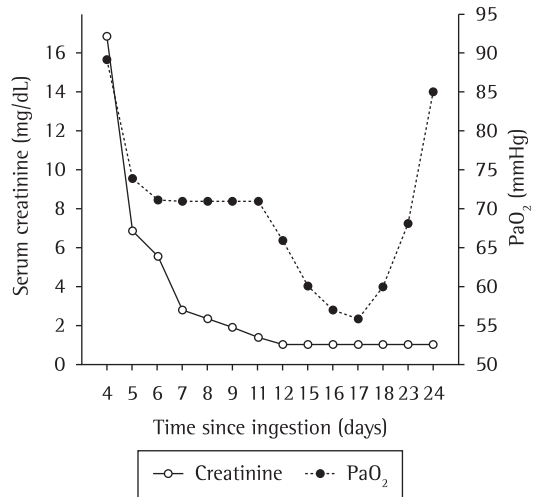
Financial support: None.

Submitted: 11 March 2010. Accepted, after review: 23 March 2010.

\*\* A versão completa em português deste artigo está disponível em [www.jornaldepneumologia.com.br](http://www.jornaldepneumologia.com.br)

On physical examination, blisters and ulcerations were observed in the mouth and on the tongue. The patient presented with elevated creatinine levels, leukocytosis, hyponatremia, and metabolic acidosis, with normal liver function and normal oxygenation. Levels of serum creatine and PaO<sub>2</sub> are shown in Figure 1. Chest X-ray findings at admission were normal (Figure 2a). Although the patient was not admitted until post-ingestion day 4, the sodium dithionite urine test result (for paraquat) was still positive at admission. He was submitted to hemodialysis and immunosuppressive therapy with cyclophosphamide, methylprednisolone, and dexamethasone, according to the protocol recommended by Lin et al.<sup>(3)</sup> In addition, he received N-acetylcysteine.

On the second day of hospital admission (post-ingestion day 6), the patient presented hemoptysis. A chest X-ray taken on post-ingestion day 8 showed localized alveolar infiltrate (Figure 2b). Pulmonary opacities, pneumomediastinum, pneumothorax, and subcutaneous emphysema were detected on a chest CT scan (Figure 3). On the seventh day of hospital admission, pulmonary gas exchange parameters worsened (Figure 1), and the patient was submitted to a second course of the same immunosuppressive therapy. Subsequently, despite of an episode of febrile neutropenia, he gradually recovered and was discharged four weeks later in good condition, with no need for home oxygen therapy. Four months later, the patient was working again and had no complaints, except for dyspnea after

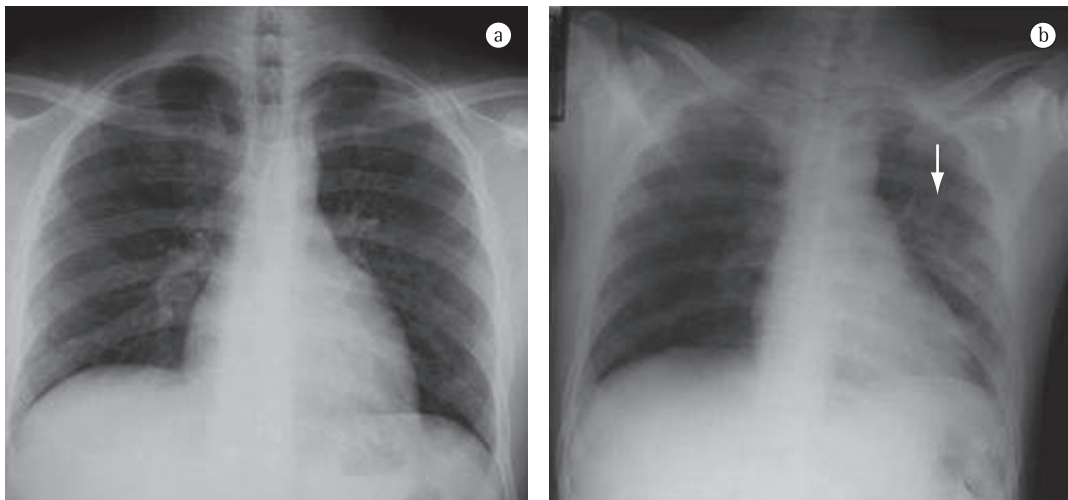


**Figure 1** - Evaluation of renal function and gas exchange (FiO<sub>2</sub> = 21%) during hospitalization.

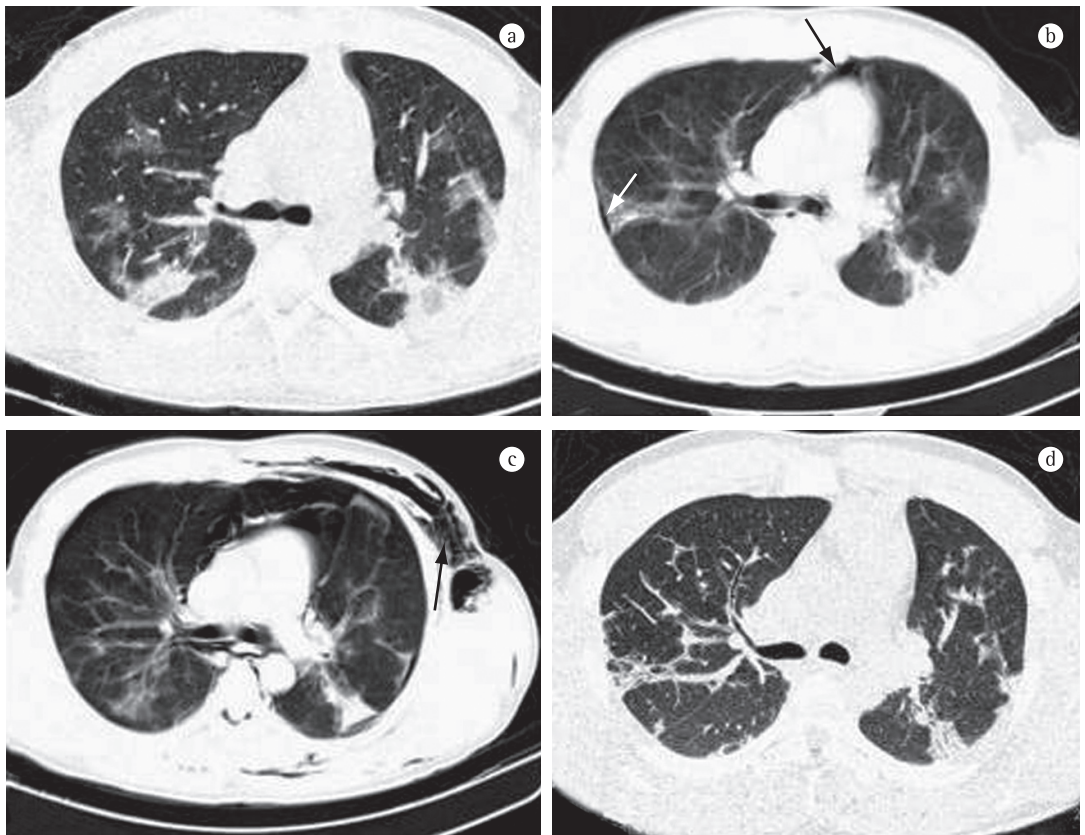
intense physical exertion. On chest auscultation, crackles were still heard in the lower lung fields, and there was wheezing throughout, together with pleural rub in the right hemithorax. The chest CT scan at four months after discharge is also shown in Figure 3.

## Discussion

We have presented a typical case of moderately severe paraquat poisoning. However, the outcome was positive, which is rare, and this was probably due to the immunosuppressive therapy, despite the fact that treatment was started long after the ingestion.



**Figure 2** - Plain chest X-ray on post-ingestion days 4 (a) and 8 (b). There are no radiological changes in a). Localized alveolar infiltrate is shown in b) (white arrow).



**Figure 3** – Chest CT scans on post-admission days 8, 15, and 18 (i.e., post-ingestion days 12, 19, and 22: a, b, and c, respectively), as well as at four months after discharge (d). In a), there are diffuse ground-glass opacities; b) shows a small pneumothorax (white arrow) and pneumomediastinum (black arrow); c) shows subcutaneous emphysema (black arrow) and an increase in pneumomediastinum volume; and d) demonstrates partial reversal of the CT findings.

Most cases of paraquat poisoning are accidental or are secondary to suicide attempts. (1) Cases of moderate-to-severe poisoning are usually secondary to ingestion of 20-50 mg/kg of body weight. Common clinical findings are gastrointestinal symptoms, acute renal failure, pulmonary hemorrhage, and late pulmonary fibrosis. Generally, death, from respiratory failure, occurs within three weeks after the ingestion. In cases of massive intake (> 50 mg/kg of body weight), death occurs a few hours after ingestion, due to multiple organ failure. (2)

The toxicity of paraquat results from the fact that it inhibits the reduction of NADP to NADPH, resulting in the overproduction of reactive oxygen species that destroy the lipids of cell membranes. Consequently, there is inflammation, with leukocyte recruitment and late pulmonary fibrosis, leading to hypoxemia unresponsive to treatment. This pathophysiology

is usually confirmed by radiological findings, (4) such as the diffuse ground-glass opacities demonstrated in the present case report. (4) In addition, we observed pneumomediastinum, pneumothorax, and subcutaneous emphysema, which are complications commonly ascribed to the pulmonary toxicity of paraquat. (5)

There is no specific treatment for paraquat poisoning. General therapeutic measures are indicated to prevent paraquat absorption through the digestive tract and to increase its excretion. Gastric lavage with Fuller's earth or activated charcoal is generally used to prevent paraquat absorption. Increasing paraquat excretion through hemoperfusion is often indicated as the appropriate next step. Unfortunately, due to the long delay between ingestion and emergency room admission, not all measures were taken in this case. Mortality rates are significantly high, even if best practice is followed and there is full

access to the all of supportive measures described. New approaches, including immunosuppressive therapy and treatment with antioxidants, are being studied in selected patients with poor prognostic factors, such as high dose ingestion, systemic involvement, ingestion attributed to a suicide attempt, pneumomediastinum, and strongly positive qualitative test results.<sup>(2)</sup> In the present case, despite the fact that 96 h had passed since the paraquat ingestion, these new therapeutic approaches were used, because the clinical condition of the patient had deteriorated. We had to assume that the poisoning was life-threatening, because a quantitative determination of plasma levels of paraquat, high levels being associated with greater mortality, was not available in our department.

In the present case, various findings indicated a poor prognosis. Therefore, immunosuppressive therapy and treatment with antioxidants were indicated in order to interrupt the inflammatory process. Although further studies are required in order to determine the true benefits of this type of therapy in paraquat poisoning, the

progressive improvement of the pulmonary gas exchange parameters and the unusually positive outcome documented here are certainly quite heartening and could lead to the development of new protocols for the treatment of this serious condition.

## References

1. Vale JA, Meredith TJ, Buckley BM. Paraquat poisoning: clinical features and immediate general management. *Hum Toxicol.* 1987;6(1):41-7.
2. Dinis-Oliveira RJ, Duarte JA, Sánchez-Navarro A, Remião F, Bastos ML, Carvalho F. Paraquat poisonings: mechanisms of lung toxicity, clinical features, and treatment. *Crit Rev Toxicol.* 2008;38(1):13-71.
3. Lin JL, Lin-Tan DT, Chen KH, Huang WH. Repeated pulse of methylprednisolone and cyclophosphamide with continuous dexamethasone therapy for patients with severe paraquat poisoning. *Crit Care Med.* 2006;34(2):368-73.
4. Lee SH, Lee KS, Ahn JM, Kim SH, Hong SY. Paraquat poisoning of the lung: thin-section CT findings. *Radiology.* 1995;195(1):271-4.
5. Im JG, Lee KS, Han MC, Kim SJ, Kim IO. Paraquat poisoning: findings on chest radiography and CT in 42 patients. *AJR Am J Roentgenol.* 1991;157(4):697-701.

## About the authors

---

### *Fábio Fernandes Neves*

Attending Physician. University of São Paulo at Ribeirão Preto School of Medicine *Hospital das Clínicas*, Ribeirão Preto, Brazil.

### *Romualdo Barroso Sousa*

Physician. University of São Paulo at Ribeirão Preto School of Medicine *Hospital das Clínicas*, Ribeirão Preto, Brazil.

### *Antônio Pazin-Filho*

Professor. University of São Paulo at Ribeirão Preto School of Medicine, Ribeirão Preto, Brazil.

### *Palmira Cupo*

Professor. University of São Paulo at Ribeirão Preto School of Medicine, Ribeirão Preto, Brazil.

### *Jorge Elias Júnior*

Professor. University of São Paulo at Ribeirão Preto School of Medicine, Ribeirão Preto, Brazil.

### *Marcello Henrique Nogueira-Barbosa*

Professor. University of São Paulo at Ribeirão Preto School of Medicine, Ribeirão Preto, Brazil.